



PATIENT

Kiara Dio

PRESENTING CLINICAL SIGNS

pancreatitis vs chronic gastritis Temp 104.2

SPECIES

Caine

BREED

Dachshund

SEX

FS

AGE

5

WEIGHT

15.2

INTERPRETED BY

R. McKenzie Daniel,
DVM, DABVP
(Canine and Feline)

IMAGING PERFORMED BY

Jenn

HOSPITAL NAME

Rockaway Animal
Hospital

REFERRING VET

Dr Harrs

INVOICE 23299

DATE 12/20/2025

ULTRASONOGRAPHIC EXAMINATION OF THE ABDOMEN

Urinary System

The urinary bladder, trigone, cystourethral junction, and visible pelvic urethra to a depth of 2 cm exhibited normal thickness and tone. Anechoic urine was present in the lumen with no evidence of urine/lumen sediment, mineral, or calculi. The ureteral papillae were normal. The ureters were not visible which is normal. No evidence of inflammatory or neoplastic changes was noted.

Normal size and margination were present in the kidneys. A normal 1:3 cortex / medulla ratio and normal corticomedullary definition were maintained. The echogenicity of the cortex was similar to or slightly less than normal liver parenchyma while the medulla echogenicity was hypoechoic to the cortex with no evidence of pelvic dilation. The left kidney measured 4.2 cm in length. The right kidney measured 4.0 cm in length.

The area of the aortic trifurcation was free of pathology.

Adrenal Glands

The left adrenal gland was uniform in size and contour with a uniformly hypoechoic parenchyma. The left adrenal gland measured 0.47 cm width at the caudal pole. The right adrenal gland was uniform in size and contour with a uniformly hypoechoic parenchyma. The right adrenal gland measured 0.59 cm width at the caudal pole.

Spleen

The spleen exhibited a finely textured and homogenous parenchyma which was hyperechoic to the liver and renal cortical parenchyma. The capsule was smooth and regular without apparent expansion. The splenic vasculature at the hilus was normal in volume with no evidence of congestion or thrombosis. Acute to chronic inflammatory, neoplastic, or benign parenchyma changes were not noted.

Liver/Gallbladder

The liver was subjectively normal in size, structure, and contour. The liver parenchyma was uniform and hypoechoic to the spleen with a mild coarse echotexture. Normal vascular volume. The hepatic and portal vasculature were normal in appearance without signs of congestion. The gallbladder was non-distended in size with thin walls and primarily anechoic luminal content. The cystic and common bile ducts were normal.

Gastrointestinal

The stomach presented intact wall layering with a normal wall layer ratio. The lumen of the stomach was empty with no signs of ileus, obstruction or foreign material. The gastric body wall measured 0.30 cm in width.

The small intestine presented intact wall layering with 1:3 muscularis/mucosa ratio. The lumen of the small intestine was empty with no signs of mechanical/metabolic ileus, obstruction or foreign material.

Normal visible colon wall layers were present with apparent formed feces in lumen.



PATIENT *Pancreas*

Kiara Dio The area of the pancreas was sonographically normal.

Free Abdomen

SPECIES

No omental masses, overt lymphadenopathy or peritoneal effusion was present.

Caine

ULTRASONOGRAPHIC FINDINGS

BREED

Primary

Dachshund

- Sonographically unremarkable empty gastrointestinal tract.
- Normal area of pancreas.

SEX

INTERPRETATION OF THE FINDINGS & FURTHER RECOMMENDATIONS

FS

No evidence of visceral pathology. Specifically, no sonographic criteria for gastritis or active pancreatitis. If gastrointestinal signs are present in this patient, mild gastritis / gastroenteritis and low-grade pancreatitis may present sonographically normal. Correlation with a spec cPL or GI panel to include PLI-TLI/cobalamin and folate, if clinically indicated, may be considered. The definitive cause of the fever was not obvious. Three view chest radiographs are recommended if not done to assess for occult thoracic pathology. Supportive care is indicated.

AGE

5

WEIGHT

15.2

INTERPRETED BY

R. McKenzie Daniel,
DVM, DABVP
(Canine and Feline)

IMAGING PERFORMED BY

Jenn

HOSPITAL NAME

Rockaway Animal
Hospital

REFERRING VET

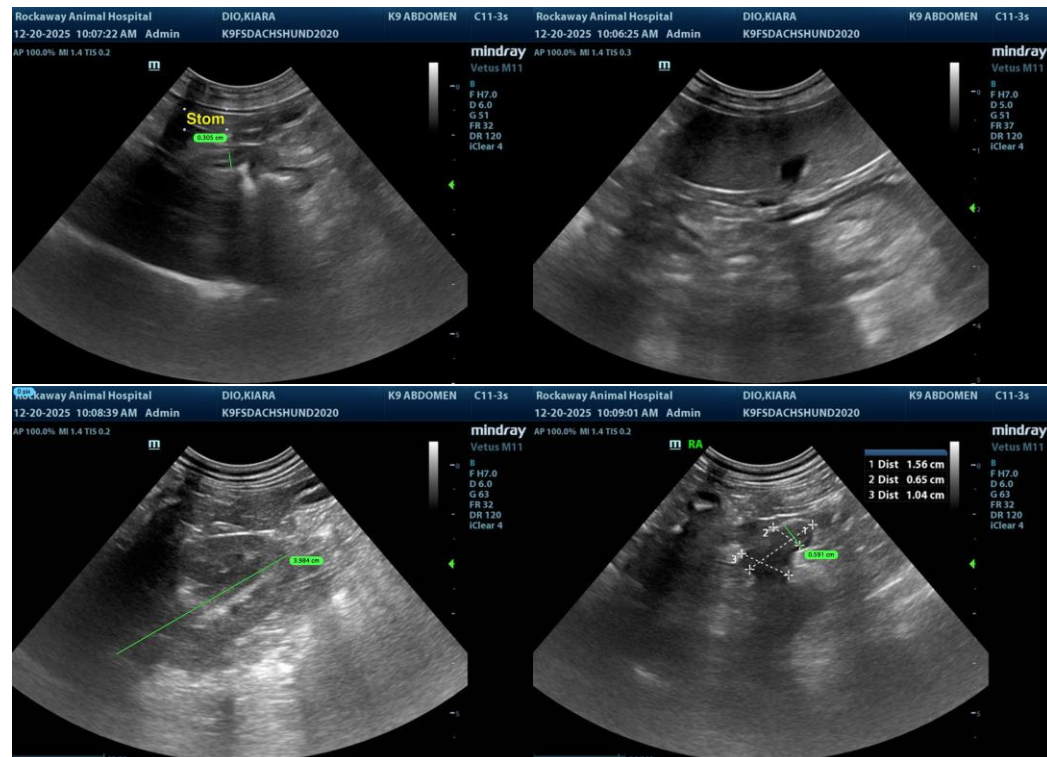
Dr Harrs

INVOICE

23299

DATE

12/20/2025





PATIENT

Kiara Dio

SPECIES

Caine

BREED

Dachshund

SEX

FS

AGE

5

WEIGHT

15.2

INTERPRETED BY

R. McKenzie Daniel,
DVM, DABVP
(Canine and Feline)

IMAGING PERFORMED BY

Jenn

HOSPITAL NAME

Rockaway Animal
Hospital

REFERRING VET

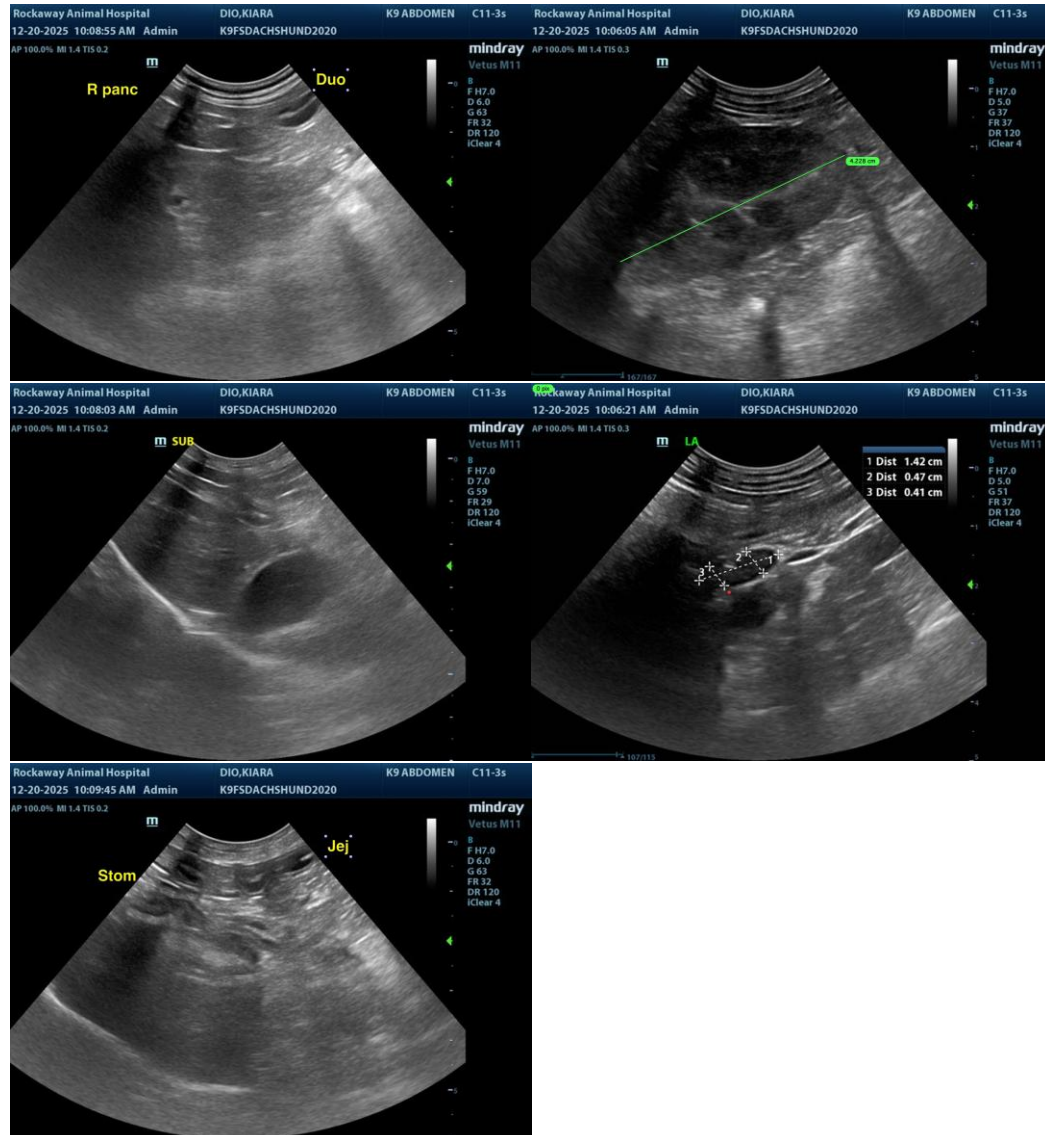
Dr Harrs

INVOICE

23299

DATE

12/20/2025



The information and recommendations provided are based on the images presented by the referring veterinarian/sonographer. No evaluation can be communicated regarding pathology that was not visible in the image/video clips provided.

Thank you for this referral. If the clinical or image interpretation does not parallel your findings or if I can be of any further assistance, please contact me.

R. McKenzie Daniel, DVM, DABVP (Canine/Feline Practice)
info@sonopath.com